

## Technical Note

## Combined Anterior and Anterolateral Stabilization of the Knee With the Hamstring Tendons

Henri Robert, M.D., and Jean-Philippe Vincent, M.D.

**Abstract:** Anterior cruciate ligament reconstruction allows good control of sagittal laxity but insufficient rotary laxity control. Our objective is to describe an original lateral extra-articular tenodesis using gracilis in addition to an intra-articular reconstruction using the semitendinosus in a short 4-strand graft. The principles are as follows: The femoral tunnel for intra-articular and extra-articular reconstruction is unique, the femoral attachment is posterior and proximal to the lateral epicondyle, the graft is under the lateral collateral ligament, and the tibial insertion is isometric from 0° to 60° between the Gerdy tubercle and the fibular head.

The involvement of the anterolateral knee structures in total rupture of the anterior cruciate ligament (ACL) has been known by several authors for many years (Segond, Hugston, and Muller).<sup>1-3</sup> These authors have clearly highlighted the roles of these structures in controlling the internal rotation of the knee. Many procedures using a long strip of the iliotibial band (ITB) to strengthen the anterolateral capsular structures were described by Lemaire, MacIntosh, Ellison, Losee, and Andrews in the early 1980s, but few publications were reported.<sup>4-8</sup> Lateral extra-articular tenodesis (LET) was initially performed without concomitant intra-articular anterior cruciate ligament reconstruction (ACLR). The extra-articular augmentations fell out of favor, notably in the United States, after many publications. Many recent articles have “revisited” the anatomy of the lateral aspect of the knee, and the anterolateral ligament (ALL) has been “rediscovered” by several authors. There is today a consensus on its anatomic insertions.<sup>9,10</sup> The function

of the anterolateral structures in rotary control in synergy with the ACL has also been shown by numerous recent biomechanical works.<sup>10-12</sup> They concluded that the anterolateral structures act as a secondary stabilizer of anterior laxity and internal rotation after ACL rupture.

ACLR allows good control of sagittal laxity but insufficient rotary laxity control. Up to 30% of patients complain of residual instability after ACLR.<sup>13</sup> Currently, lateral extra-articular procedures are performed either as anatomic anterolateral ligament reconstructions (ALLRs) or tenodeses.<sup>14-16</sup> We must distinguish the anatomic reconstructions of the ALL (replication of the anatomy) from the isometric LET.

Our purpose is to describe an original LET using gracilis in addition to an intra-articular reconstruction using the semitendinosus in a short 4-strand autograft (ACLR according to Tape Locking Screw procedure) (Fig 1). The principles are summarized in Table 1.

### Surgical Technique

The physical examination, performed with the patient under general anesthesia, is focused on the Lachman and pivot-shift grades. When gross Lachman plus pivot-shift findings are present, LET after ACLR is considered.

The patient is placed in the supine position with the knee in 90° of flexion, stabilized with a lateral support (Maquet Getinge Group, Rastatt, Germany) and a foot bar (Maquet Getinge Group) so that the knee can be mobilized from full extension up to 120° of flexion. Key anatomic landmarks are drawn in Figure 2. A pneumatic tourniquet is not routinely used, but we request

From the Orthopedic Surgery Unit, Haut-Anjou Hospital, Château-Gontier, France (H.R.); and Private Hospital Océane, Vannes, France (J-P.V.).

The authors report no conflicts of interest in the authorship and publication of this article. Full ICMJE author disclosure forms are available for this article online, as supplementary material.

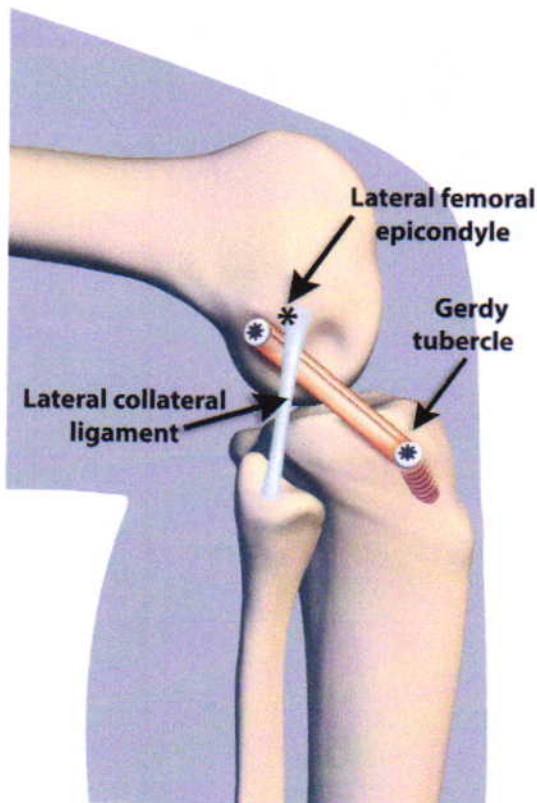
Received June 15, 2020; accepted October 4, 2020.

Address correspondence to Henri Robert, M.D., Orthopedic Surgery Unit, Haut-Anjou Hospital, 1 quai Dr. Lefevre, 53200, Château-Gontier, France. E-mail: henri.robert36@gmail.com

© 2020 by the Arthroscopy Association of North America. Published by Elsevier. This is an open access article under the CC BY-NC-ND license (<http://creativecommons.org/licenses/by-nc-nd/4.0/>).

2212-6287/201181

<https://doi.org/10.1016/j.eats.2020.10.003>



**Fig 1.** Right knee in 90° of flexion. The lateral extra-articular tenodesis is passed underneath the lateral collateral ligament.

hypotension from the anesthesiologist. The technique is shown in detail in [Video 1](#).

### Step 1: Arthroscopic Evaluation

An anterolateral viewing portal and an anteromedial working portal are used. After confirmation of the ACL rupture, meniscal and chondral lesions are managed when necessary.

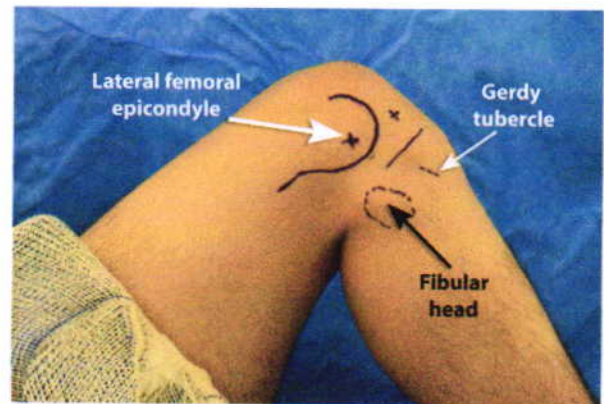
### Step 2: Graft Harvesting

A 3-cm-long, oblique incision is made over the pes anserinus. The sartorius is retracted superiorly, and the gracilis and semitendinosus tendons are bluntly dissected and harvested using an open stripper (FH Orthopedics, Heimsbrunn, France). Tendon lengths are measured ([Fig 3](#)).

**Table 1.** Principles of LET

Unique femoral tunnel for intra-articular reconstruction and extra-articular tenodesis
Femoral attachment is posterior and proximal to lateral epicondyle
Graft is posterior to center of rotation of knee so that it is tight near knee extension
Isometry from 0°-60°, resulting in minimal length change during flexion cycle
Graft is deep to LCL, which acts as pulley
Isometric tibial insertion between Gerdy tubercle and fibular head

LCL, lateral collateral ligament; LET, lateral extra-articular tenodesis.



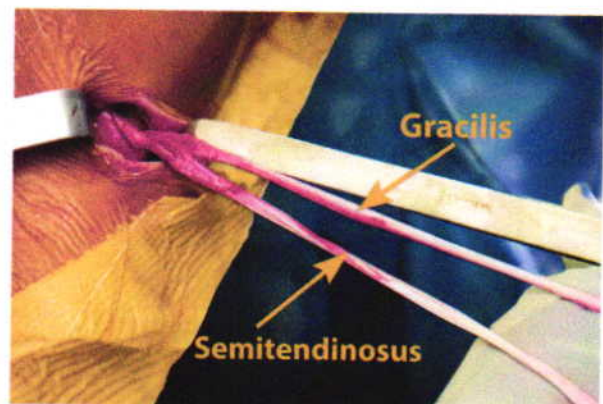
**Fig 2.** Knee position, lateral view. The patient is placed in the supine position with the right knee in 90° of flexion, stabilized with a lateral support and a foot bar. Key anatomic landmarks are drawn.

### Step 3: Graft Preparation


A 4- or 5-strand semitendinosus short graft (50-60 mm long according to the patient's height) is prepared on the graft master ([Video 1](#)). The strands are joined by means of 3 or 4 cross stitches using a No. 1 Vicryl suture (Ethicon, Somerville, NJ). A nonabsorbable tape (polyethylene terephthalate polyester) is passed through each tendon loop. The end of the gracilis tendon is passed through the femoral loop to obtain a 2-strand gracilis tendon (a graft whose length must be >12 cm). The construct is sized and submitted to a high (<300 N) and short (<1 minute) pre-tension ([Fig 4](#)).

### Step 4: Lateral Femoral Approach

A 4- to 5-cm skin incision centered on the lateral epicondyle, in line with the ITB, is performed. The ITB is sharply divided to expose the lateral condyle. The exit point from the femoral tunnel is marked with an



**Fig 3.** Right knee, medial view. Graft harvesting. A 3-cm-long, oblique incision is made over the pes anserinus. The sartorius is retracted superiorly, and the gracilis and semitendinosus tendons are bluntly dissected and harvested using an open tendon stripper. Tendon lengths are measured.



**Fig 4.** (A) Graft preparation. A 4- or 5-strand semitendinosus short graft is prepared on the graft master. The strands are joined by means of 3 or 4 cross stitches using a No. 1 Vicryl. A nonabsorbable tape is passed through each tendon loop. The end of the gracilis tendon is passed through the femoral loop to obtain a 2-strand gracilis tendon. (B) Graft sizing. The construct is sized and submitted to a high (<300 N) and short (<1 minute) pre-tension.

electric cautery device. This landmark is 10 mm proximal and posterior to the lateral epicondyle. It will constitute the femoral attachment of the intra-articular graft and the upper attachment of the LET. The proximal part of the lateral collateral ligament (LCL) is identified by blunt dissection. The LCL is incised at its anterior and posterior borders, and a small pulley is dug with scissors (Fig 5).

#### Step 5: Femoral Tunnel

By anterolateral visualization, the center of the femoral native footprint, according to the anatomic reconstruction concept, is marked with an angulated awl ("pilot hole") (Fig 6A). The tip of the femoral aimer (FH Orthopedics) is inserted into the medial portal and placed in the intra-articular hole (pilot hole). The guide is fixed over the extra-articular femoral landmark previously set. The guide has to be perpendicular to the femoral condyle (the angle of the femoral guide is set to 90°), and a 2.4-mm-diameter K-wire is inserted into the femoral condyle with an outside-in, retrograde drilling technique. A sagittal radiograph may be used to

ensure that the K-wire is properly positioned (Fig 6B). An 8-, 9-, or 10-mm reamer (depending on the diameter of the femoral loop) is used to drill a continuous tunnel.

#### Step 6: Tibial Tunnel of Intra-articular Graft

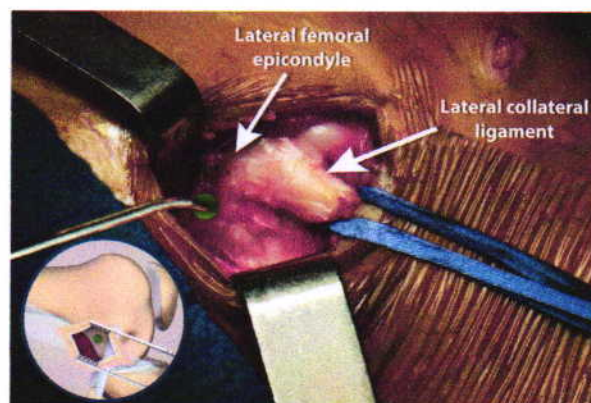
The tip of the tibial aimer (FH Orthopedics) is placed as close as possible to the base of the medial tibial eminence in the center of the ACL remnant. The angle of the tibial guide is set to 60°. A continuous 4.5-mm-diameter tunnel is reamed. An all-inside retrograde socket (15 mm deep) is reamed manually at the diameter and length of the tibial graft end (Fig 7).

#### Step 7: Penetration of Intra-articular Graft

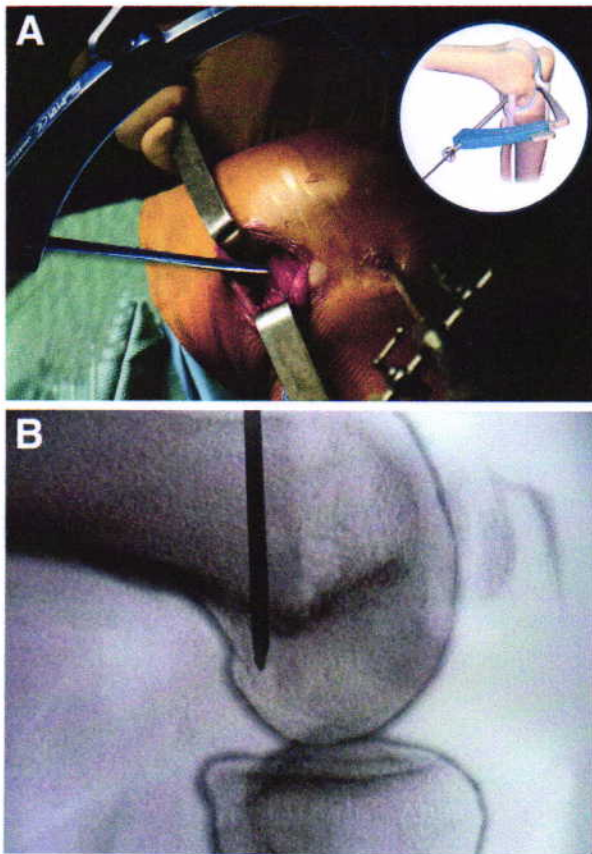
The traction sutures are passed through the femoral and tibial tunnels in an outside-in direction and then brought out with a grasper through the anteromedial portal. The femoral end (gracilis plus tapes) is pulled out of the femoral tunnel; then, the tibial tapes are pulled out of the tibial tunnel, and each tendon end fully enters its socket. Sufficient penetrations of each loop in both sockets are checked (Fig 8).

#### Step 8: Femoral Fixation

While the tapes are being pulled and the gracilis is being separated, a guide pin is inserted into the femoral tunnel; then, a bioabsorbable (poly-L-lactic acid- $\beta$ -tricalcium phosphate) or PEEK (polyether ether ketone) screw (diameter, 10 mm; length, 20 mm) (FH Orthopedics) is inserted into the femoral tunnel (Fig 9).



**Fig 5.** Right knee, lateral view. Lateral femoral approach. A 4- to 5-cm skin incision centered on the lateral epicondyle, in line with the iliotibial band, is performed. The iliotibial band is sharply divided to expose the lateral condyle. The exit point from the femoral tunnel is marked with an awl. This landmark is 10 mm proximal and posterior to the lateral epicondyle. It will constitute the femoral attachment of the intra-articular graft and the upper attachment of the lateral extra-articular tenodesis. The proximal part of the lateral collateral ligament is identified by blunt dissection. The lateral collateral ligament is incised at its anterior and posterior borders, and a small pulley is dug with scissors.



**Fig 6.** Right knee in 90° of flexion, lateral view. (A) Femoral tunnel. The tip of the femoral aimer is inserted into the medial portal and placed at the intra-articular femoral landmark (pilot hole). The guide is fixed over the extra-articular femoral landmark previously set. The guide has to be perpendicular to the femoral condyle and horizontal on the frontal view (angulation set at 90°), and a 2.4-mm-diameter K-wire is inserted into the femoral condyle with an outside-in, retrograde drilling technique. A reamer of 8, 9, or 10 mm (depending on the diameter of the femoral loop) is used to drill a continuous tunnel. (B) A sagittal radiograph may be used to ensure that the K-wire is properly positioned.

#### Step 9: Tibial Fixation of Intra-articular Graft

While the tibial tapes are being pulled, a bioabsorbable or PEEK screw (diameter, 10 mm; length, 25 mm) (FH Orthopedics) is inserted into the tibial tunnel at 10° to 20° of flexion and neutral rotation (Fig 10).

#### Step 10: Tibial Tunnel of LET

The double loop of gracilis is sized (usually 5-6 mm) (Fig 11). To determine the isometric point in the tibia, 2 solutions are possible. A compass can be used to locate the isometric tibial attachment between the fibular head and the Gerdy tubercle. One tip is implanted in the head of the femoral screw, and the other determines the best isometric tibial placement. Femoral

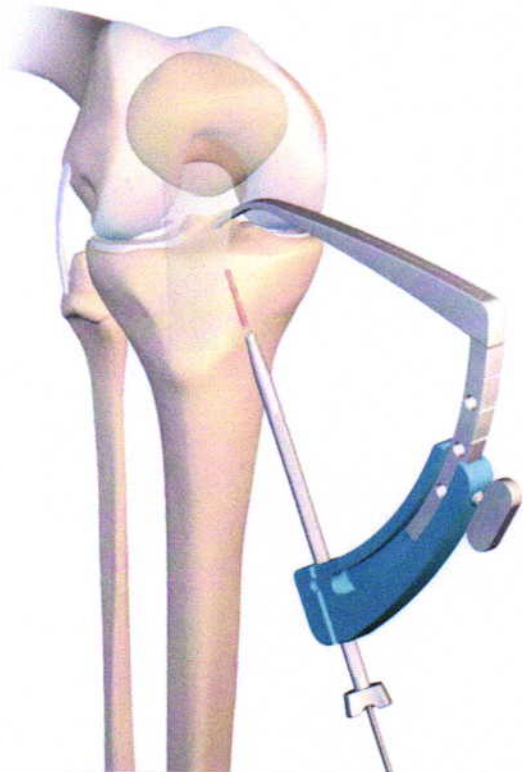
tapes looped around a K-wire can also be used to determine the tibial placement (Fig 12). In both cases, the lengthening or shortening of the compass or tapes in flexion-extension of the knee is checked to determine the best tibial placement. An oblique tibial tunnel (with the angle of the tibial guide set to 60°) is drilled with a 6- or 7-mm reamer depending on the graft size (Fig 13).

#### Step 11: Passage of LET

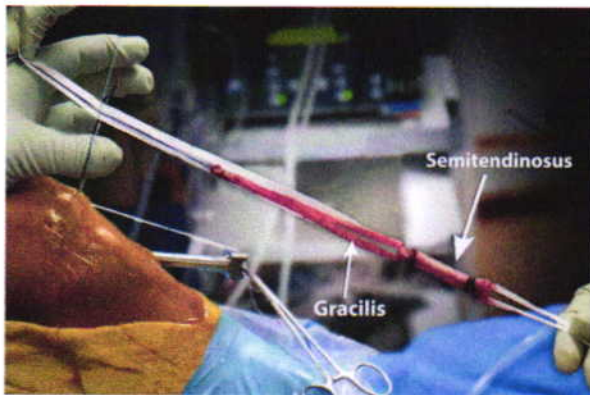
A whipstitch suture is applied to both free ends of the gracilis, using a resorbable suture (No. 1 Vicryl). The loop of the gracilis is passed underneath the LCL and under the ITB by use of a Kelly clamp (Fig 14).

#### Step 12: Tibial Fixation of LET

The loop is tensioned and secured in the tunnel using a bioabsorbable or PEEK screw (diameter, 7 mm; length, 25 mm) (FH Orthopedics) with the knee in extension and the foot in neutral position (Fig 15).



**Fig 7.** Right knee, anterior view. Tibial tunnel of intra-articular graft. The tip of the tibial aimer is placed as close as possible to the base of the medial tibial eminence in the center of the anterior cruciate ligament remnant. A continuous 4.5-mm-diameter tunnel is reamed. An all-inside retrograde socket (15 mm deep) is reamed manually at the diameter and length of the tibial loop.



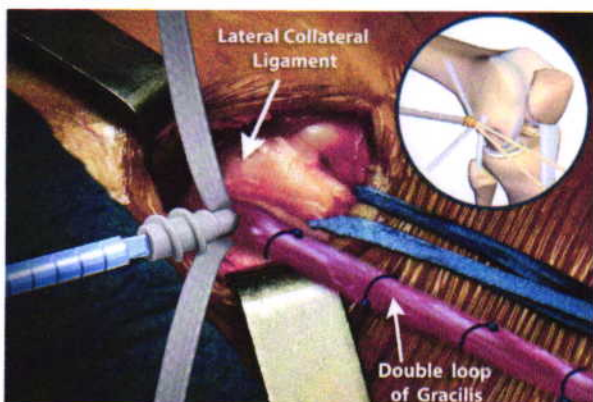
**Fig 8.** Right knee, lateral view. Penetration of intra-articular graft. Traction sutures are passed through the femoral and tibial tunnels and then brought out with a grasper through the anteromedial portal. The femoral end (gracilis plus tapes) is pulled out of the femoral tunnel; then, the tibial tapes are pulled out of the tibial tunnel, and each tendon loop fully enters its socket.

### Step 13: Testing and Closure

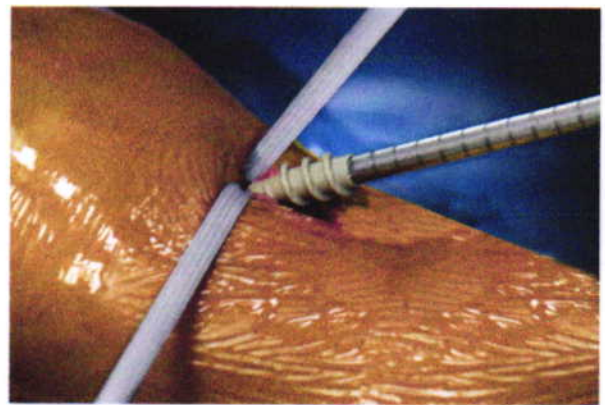
At the end of the procedure, with the graft tensed at 30° and slightly relaxed at 90°, stability tests are performed. The wounds are irrigated and closed in 2 layers (subcutaneous and skin). Intra-articular injection of 20 mL of ropivacaine, 30 mg of ketoprofen, and 1 g of tranexamic acid is performed. A compression stocking is applied from the foot to the upper thigh, and a freezing brace lies on the knee.

### Step 14: Postoperative Rehabilitation

Full weight bearing and mobilization without limitation are recommended immediately. Crutches are recommended for 2 weeks. Cycling is allowed at 1 month; running, at 3 months; and contact sporting activities, after 8 months.



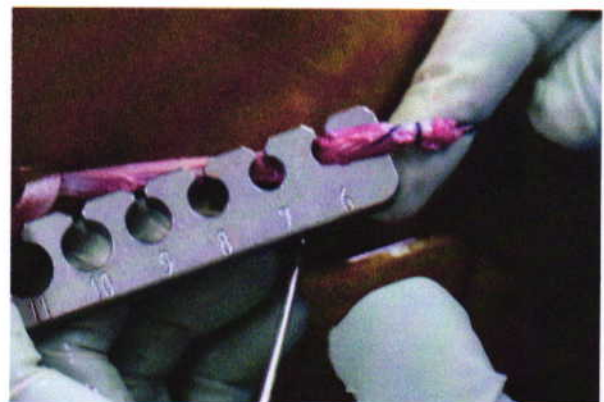**Fig 9.** Right knee, anterolateral view. Fixation of femoral tapes. By pulling the tapes and separating the gracilis, a guide pin is inserted into the femoral tunnel; then, a PEEK screw (diameter, 10 mm; length, 20 mm) is inserted into the femoral tunnel. The double loop of gracilis is in traction for protection and sized (usually 5-6 mm).



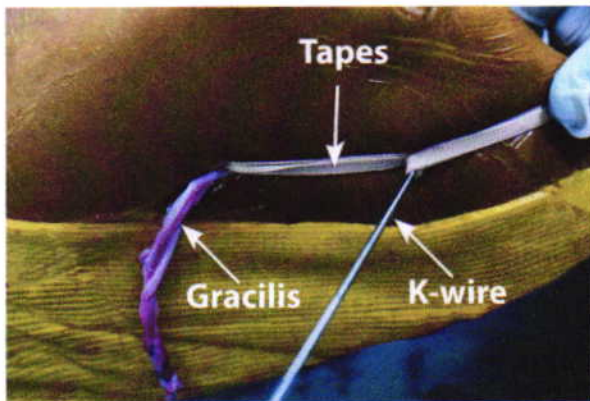
**Fig 10.** Right knee, lateral view. Tibial fixation of intra-articular graft. By pulling the tibial tapes, a PEEK screw (diameter, 10 mm; length, 25 mm) is inserted into the tibial tunnel at 10° to 20° of flexion and neutral rotation.

## Discussion

The use of an LET is logical because it is far from the center of knee rotation and because it provides a greater lever arm for controlling internal rotation. Anterolateral reconstructions have been performed since 1967 by Lemaire<sup>4</sup> with an ITB strip 12 mm wide and 70 to 80 mm long, keeping its distal insertion, passing over the LCL, and fixing it proximal and posterior to the lateral epicondyle.<sup>14</sup> The techniques of Dejour et al.,<sup>17</sup> Lutz et al.,<sup>15</sup> and Pavão et al.<sup>18</sup> used the ITB, but each technique has its particularities. Dejour et al. put the ITB under the LCL and fixed it at an isometric point proximal and posterior to the lateral epicondyle. Lutz et al. and Pavão et al. looked for an anatomic point on the femoral epicondyle. Lutz et al. used a total graft length of approximately 20 cm for the ITB. Christel and Djian<sup>19</sup> described a less invasive modification of the Lemaire technique, in which a shorter ITB strip is twisted 180° and inserted into the lateral tubercle after going under the LCL. Other authors have used the hamstring tendons.

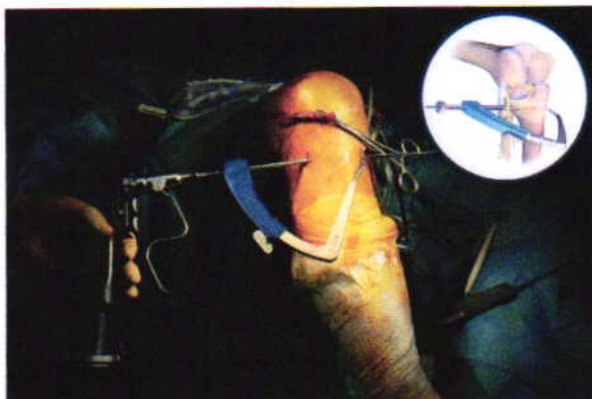


**Fig 11.** Sizing of lateral extra-articular tenodesis. A whipstitch suture is applied to both free ends of the gracilis loop, using an absorbable suture (No. 1 Vicryl), and the loop is sized.

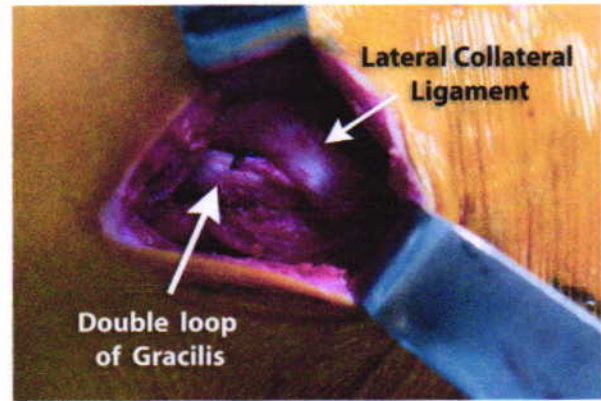


**Fig 12.** Right knee in 90° of flexion, lateral view. Tibial tunnel of lateral extra-articular tenodesis. To determine the isometric point in the tibia, 2 solutions are possible. The tapes and a K-wire can be used to identify the isometric tibial landmark between the fibular head and the Gerdy tubercle. The tapes surround the K-wire implanted in the best isometric tibial placement. A compass can also be used. In both cases, the lengthening or shortening of the compass or tapes validates the correct position.

One of the particularities of our technique is the choice of a single point on the femoral condyle for the exit of the ACL graft and the high fixation of the LET. There is a consensus on femoral positioning of the ALL, proximal and posterior to the lateral epicondyle.<sup>9,10</sup> The tibial insertion is distal to the Gerdy tubercle.<sup>9</sup> This point is determined with the compass or by using the tapes with flexion-extension movements so that the LET is tight near the knee in extension. As knee flexion increases, the graft progressively becomes laxer, allowing full range of motion and internal rotation. Inderhaug et al.<sup>20</sup> showed that an LET tensioned at 20 N and passed deep to the LCL was effective at controlling rotation with minimal overconstraint of medial rotation. If the graft is tensioned at 88 N, it causes significant overconstraint in



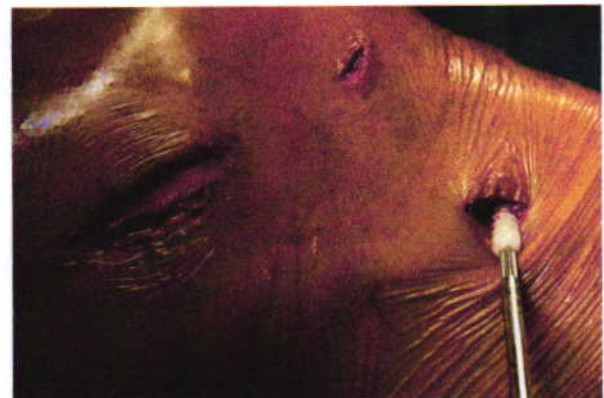**Fig 13.** Right knee, anterior view. Drilling of tibial tunnel. From the tibial isometric point, an oblique tibial tunnel (with the angle of the guide set to 60°) is drilled with a 6- or 7-mm reamer depending on the graft size.



**Fig 14.** Right knee, lateral view. Passage of lateral extra-articular tenodesis. The loop of the gracilis is passed underneath the lateral collateral ligament and under the iliotibial band by use of a Kelly clamp.

internal rotation, no matter what angle of flexion is used.<sup>21</sup> To control knee laxity, the LET has to be fixed in extension or in low flexion. The gracilis seems a good mechanical choice. The 2-strand gracilis has a maximum load to failure of approximately 200 N, slightly higher than that of the native ALL (140 N).<sup>22</sup>

The unique femoral tunnel avoids the risk of femoral tunnel convergence (ACL and LET) and of collision of the 2 fixation devices. The techniques with 2 separate tunnels appeared much more difficult to us. When performing combined ACL-LET procedures, the LET femoral tunnel should be drilled in a specific 3-dimensional orientation. The reasons for widespread abandonment of LET some 30 years ago are the high rates of knee stiffness and reoperations. It was recently shown that these adverse outcomes were not superior in a large series of 548 combined ACLR-ALLR procedures compared with isolated ACLR.<sup>23</sup>



**Fig 15.** Right knee, lateral view. Tibial fixation of lateral extra-articular tenodesis. The loop is tensioned and secured in the tunnel using a bioabsorbable screw (diameter, 7 mm; length, 25 mm) (FH Orthopedics) with the knee in extension and the foot in neutral position.

**Table 2.** Advantages, Risks, and Limitations of LET

	Advantages	Risks and Limitations
Tendon harvesting	Respect for iliotibial band	ST that is too thin requires gracilis
Hamstring size	Minimal 12-cm length for LET	If ST is too thin or gracilis is too short, Lemaire technique must be used
Femoral tunnel	Tunnel unique for ACL and LET, avoiding drill-hole convergence	Malposition of femoral tunnel
Tibial tunnel	Isometric with use of compass or tapes	Malposition of tibial tunnel
Position of knee for fixation	Knee in low flexion and neutral rotation	Overconstraint of lateral compartment

ACL, anterior cruciate ligament; LET, lateral extra-articular tenodesis; ST, semitendinosus.

Our technique cannot be performed if the length of the double-strand gracilis tendon is inferior to 12 cm (total length of the gracilis < 24 cm). In such cases, we perform a Christel-Djian procedure with a short ITB strip (7-8 cm) passed under the LCL.<sup>19</sup> Similarly, if the semitendinosus is too thin, it will be necessary to harvest the gracilis and semitendinosus intra-articularly, and an extra-articular technique, as described by Christel and Djian,<sup>19</sup> will be performed.

The advantages, risks, and limitations of the LET are summarized in Table 2. All LET procedures have been criticized for having a theoretical risk of overconstraint of the lateral compartment if fixed in external rather than neutral rotation or in high tension. There is also a risk of decreased range of motion in cases of non-isometric implantation. There is no evidence that combined ACL-LET reconstructions are associated with the increased risk of complications or the frequent reoperations reported in the 1980s.<sup>23</sup> In 2017, Devitt et al.<sup>24</sup> published a systematic review and concluded that LET in combination with ACLR did not increase the risk of osteoarthritis in the first 11 years post-operatively, contrary to reports of isolated lateral procedures.

Many articles have pointed to the high failure rate in young patients participating in high-risk pivoting sports. There are many reasons for ACLR failure: improper graft placement, concomitant soft-tissue laxity, early return to sports, and delay in ligamentization. Therefore, there is room for improvement in ACLR methods. Recent publications of comparative series and meta-analyses have shown that the addition of an extra-articular procedure to an ACLR improves internal rotation control (reduction in the pivot shift) but has no impact on patient-reported outcomes or

sagittal control.<sup>24-27</sup> Sonnery-Cottet et al.<sup>27</sup> reported significantly lower ACL rupture rates in patients undergoing combined ACLR and ALLR when compared with isolated hamstring tendon (11%) or patellar tendon autograft (16%) procedures.

There is no consensus on the definitive recommendations as to when a lateral procedure should be added to an ACLR by way of contradictory results. The indications for the LET continue to be discussed, but a consensus has emerged for primary ACLR or revision procedures (Table 3).

## References

- Segond P. Recherches cliniques et expérimentales sur les épanchements sanguins du genou par entorse. *Progres Med* 1879;7:297-299, 319-321, 340-341.
- Hughston JC, Andrews JR, Cross MJ, Moschi A. Classification of knee ligament instabilities. Part II. The lateral compartment. *J Bone Joint Surg Am* 1976;58:173-179.
- Muller W. *The Knee: form, function and ligament reconstruction*. New York, NY: Springer Verlag, 1983:40-43.
- Lemaire M. Rupture ancienne du ligament croisé antérieur du genou. *J Chir* 1967;93:311-320 [In French].
- Mac Intosh DL. The anterior cruciate ligament over the top repair. *J Bone Joint Surg* 1974;56:591-597.
- Ellison AE. Distal iliotibial-band transfer for anterolateral rotatory instability of the knee. *J Bone Joint Surg* 1979;61:330-337.
- Loose RE, Johnson TR, Southwick WO. Anterior subluxation of the lateral tibial plateau. *J Bone Joint Surg* 1978;60-A:1015-1030.
- Andrews JR, Sanders RA, Morin B. Surgical treatment of anterolateral instability: a follow-up study. *Am J Sports Med* 1985;13:112-119.
- Kiitl C, Halewood C, Stephen JM, et al. Length change patterns in the lateral extra-articular structures of the knee and related reconstructions. *Am J Sports Med* 2015;43:354-362.
- Getgood A, Brown C, Lording T, et al. The anterolateral complex of the knee: Results from the International ALC Consensus Group Meeting. *Knee Surg Sports Traumatol Arthrosc* 2019;27:166-176.
- Thein R, Boorman-Padgett J, Stone K, Wickiewicz TL, Imhauser CW, Pearle AD. Biomechanical assessment of the anterolateral ligament of the knee: A secondary restraint in simulated tests of the pivot shift and of anterior stability. *J Bone Joint Surg Am* 2016;98:937-943.

**Table 3.** Appropriate Indications for LET as Augmentation to ACLR According to Getgood et al.<sup>10</sup> and Dejour et al.<sup>17</sup>

High-grade pivot shift
Young patients returning to pivoting activities
ACL revision
Generalized ligamentous laxity or genu recurvatum

ACL, anterior cruciate ligament; ACLR, anterior cruciate ligament reconstruction; LET, lateral extra-articular tenodesis.

12. Ruiz N, Filippi GJ, Gagnière B, Bowen M, Robert HE. The comparative role of the anterior cruciate ligament and anterolateral structures in controlling passive internal rotation of the knee: A biomechanical study. *Arthroscopy* 2016;32:1053-1062.
13. Li X, Xu CP, Song JQ, Jiang N, Yu B. Single-bundle versus double-bundle anterior cruciate ligament reconstruction: An up-to-date meta-analysis. *Int Orthop* 2013;37:213-226.
14. Lemaire M, Combelles F. Plastic repair with fascia lata for old tears of the anterior cruciate ligament. *Rev Chir Orthop Reparatrice Appar Mot* 1980;66:523-525 [in French].
15. Lutz C, Sonnery-Cottet B, Imbert P, Barbosa NC, Tuteja S, Jaeger J. Combined anterior and anterolateral stabilization of the knee with the iliotibial band. *Arthrosc Tech* 2016;5:251-256.
16. Sonnery-Cottet B, Lutz C, Daggett M, et al. The involvement of the anterolateral ligament in rotational control of the knee. *Am J Sports Med* 2016;44:1209-1214.
17. Dejour D, Zaffagnini S, Ntangiopoulos P, et al. ACL reconstruction with extra-articular plasty. In: Siebold R, Dejour D, Zaffagnini S, eds. *Anterior cruciate ligament reconstruction*. Berlin: Springer—European Society of Sports Traumatology, Knee Surgery & Arthroscopy, 2014;299-316.
18. Pavão DM, Cruz RS, de Faria JLR, de Sousa EB, Barretto J. Modified Lemaire lateral tenodesis associated with an intra-articular reconstruction technique with bone-tendon-bone graft using an adjustable fixation mechanism. *Arthrosc Tech* 2019;8:e733-e740.
19. Christel P, Djian P. Antero-lateral extra articular tenodesis of the knee using a short strip of the ITB. *Rev Chir Orthop Reparatrice Appar Mot* 2002;88:508-513 [in French].
20. Inderhaug E, Stephen JM, Williams A, Amis AA. Biomechanical comparison of anterolateral procedures combined with anterior cruciate ligament reconstruction. *Am J Sports Med* 2017;45:347-354.
21. Schon JM, Moatshe G, Brady AW, et al. Anatomic anterolateral ligament reconstruction of the knee leads to overconstraint at any fixation angle. *Am J Sports Med* 2016;44:2546-2556.
22. Wytrykoski K, Swider P, Reina N, et al. Cadaveric study comparing the biomechanical properties of grafts used for knee anterolateral ligament reconstruction. *Arthroscopy* 2016;32:2288-2294.
23. Thounat M, Clowez G, Saithna A, et al. Reoperation rates after combined anterior cruciate ligament and anterolateral ligament reconstruction: A series of 548 patients from the SANTI Study Group with a minimum follow-up of 2 years. *Am J Sports Med* 2017;45: 2569-2577.
24. Devitt BM, Bouguennec N, Barfod KW, Porter T, Webster KE, Feller JA. Combined anterior cruciate ligament reconstruction and lateral extra-articular tenodesis does not result in an increased rate of osteoarthritis: A systematic review and best evidence synthesis. *Knee Surg Sports Traumatol Arthrosc* 2017;25:1149-1160.
25. Hewison CE, Tran MN, Kaniki N, Remtulla A, Bryant D, Getgood AM. Lateral extra-articular tenodesis reduces rotational laxity when combined with anterior cruciate ligament reconstruction: A systematic review of the literature. *Arthroscopy* 2015;31:2022-2034.
26. Song GY, Hong L, Zhang H, Zhang J, Li Y, Feng H. Clinical outcomes of combined lateral extra-articular tenodesis and intra-articular anterior cruciate ligament reconstruction in addressing high-grade pivot-shift phenomenon. *Arthroscopy* 2016;32:898-905.
27. Sonnery-Cottet B, Saithna A, Cavalier M, et al. Anterolateral ligament reconstruction is associated with significantly reduced ACL graft rupture rates at a minimum follow-up of 2 years: A prospective comparative study of 502 patients from the SANTI study group. *Am J Sports Med* 2017;45:1547-1557.